

NOTE 2 Venous Investigation Of The Lower Limb Using Doppler

HOW TO USE THIS APPLICATION NOTE

- **PATIENT SYMPTOMS** Verify that your patient's symptoms correspond to one or more of those listed in Figure 1.
- **DOPPLEX® EQUIPMENT REQUIRED** Select the most appropriate **Dopplex®** Pocket unit to perform the examination. For suggestion of suitable **Dopplex®** equipment, refer to Figure 2.
- **PROCEDURE** If you have the **Dopplex® Printa II** Package or **Dopplex® Reporter** Software Package (and a computer), connect your **Dopplex®** bi-directional Doppler and begin your examination, refer to Figure 3
- **LOCATING ARTERIES** Figure 4 suggests probe position for locating an vein.
- **EXAMINATION RESULTS** Taking careful note of your **Dopplex®** display and venous waveforms (if applicable), refer to Figure 5 overleaf and compare your examination results with those shown.
- **NOTES** Refer to Figure 6 overleaf for general notes relating to this form of examination for venous disease.

FIGURE 1 PATIENT SYMPTOMS

- VARICOSE VEINS
- VARICOSE ECZEMA
- VENOUS EDEMA
- POST-THROMBOTIC SYNDROME
- SWELLING
- VENOUS ULCERS

FIGURE 2 DOPPLEX EQUIPMENT REQUIRED

Multi, Maxi or *Rheo Dopplex®* unit, 5MHz probe, (deep and superficial veins) or 8MHz probe, (superficial veins), **Dopplex® Printa II** Package or *Reporter* Software Package.

FIGURE 3 PROCEDURE

- With patient standing encourage relaxation by holding frame or bar, and ensure pulse rate is stable.
- Connect *Printa II* Package to your bi-directional Doppler.
- Ensure ambient temperature is comfortable and apply gel.
- Hold probe between forefinger and thumb at 45° angle, directed proximally.
- Commence examination at superficial femoral vein in the upper thigh and identify flow by applying distal calf compression.
- Check display for directional flow, and record waveform.
- Proceed to the popliteal vein and follow the same procedure as for the superficial femoral vein.
- The long saphenous and short saphenous veins can then be examined.
- The sapheno-femoral and sapheno-popliteal junctions are identified by placing the probe over the groin and popliteal fossa respectively and augmenting flow by tapping the appropriate vein distally.

FIGURE 4 LOCATING ARTERIES

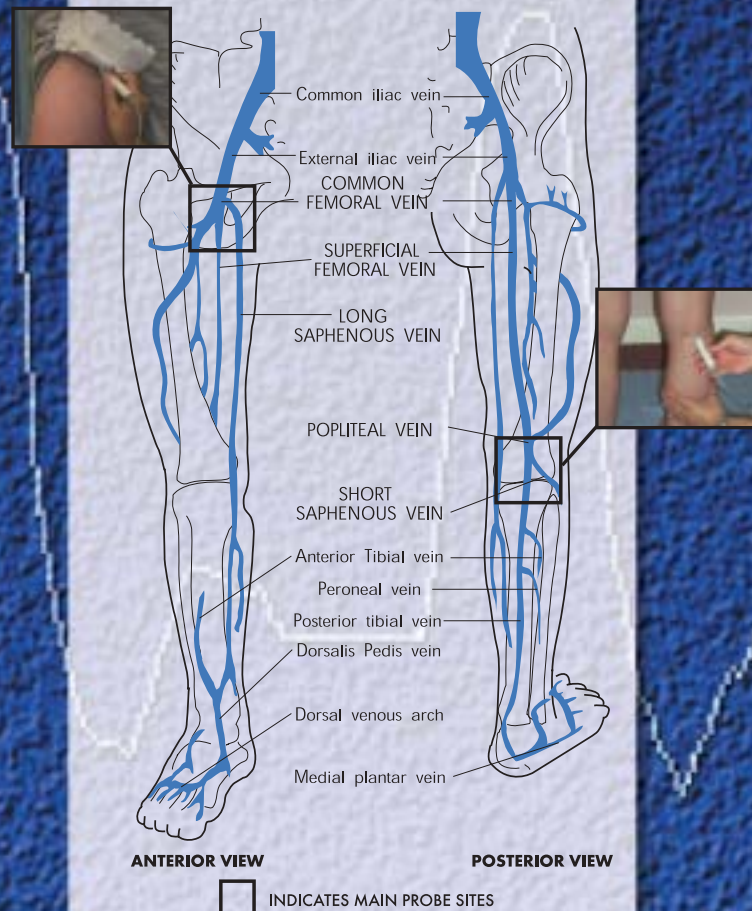


FIGURE 5 EXAMINATION

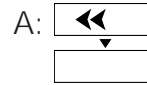
NORMAL SUPERFICIAL FEMORAL VEIN

Manual compression of the calf distal to the site of examination increases or 'augments' venous blood flow.

With the Doppler probe pointing towards the heart, arrows on the **Dopplex**® display will indicate antegrade flow (away from the probe). No retrograde flow (towards the probe) will be present.

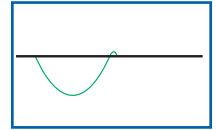
This response also confirms the substantial patency of the venous system between the site of examination and the site of manual compression (calf augmentation).

DOPPLEX DISPLAY



EXAMPLE OF NORMAL FLOW

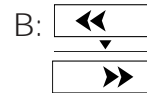DOPPLEX WAVEFORM



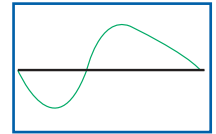
DEEP VENOUS INCOMPETENCE

Valvular reflux on distal calf compression will result in an augmented signal in an antegrade direction, immediately followed by retrograde flow.

Arrows on the **Dopplex**® display will indicate flow away from the probe, closely followed the flow towards the probe.



EXAMPLE OF DEEP VENOUS INCOMPETENCE



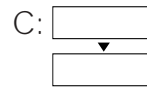
OCCLUSION

Occlusion of the superficial femoral vein will result in a Doppler signal being obtained either spontaneously or during calf compression.

The flow pattern of a complete proximal occlusion (i.e., external iliac or common femoral vein) will depend on the residual compliance of the veins between the probe and the obstruction. However, this will usually result in a reduction in strength and duration of the signal. The flow pattern of a distal obstruction during calf compression will depend on the collateralization. It should be noted that this will usually result in a reduction and delay of the augmented signal.

Long and short saphenous and popliteal veins.

Results similar to those obtained with the superficial femoral vein will be observed upon examination of the long saphenous, short saphenous and popliteal veins.



EXAMPLE OF OCCLUSION




FIGURE 6 NOTES

Gross superficial incompetence may interfere with detection of flow in deep veins. This can be minimized by placing a superficial venous tourniquet proximal to the probe.

A Trendelenburg can be performed to confirm long saphenous incompetence. A superficial venous tourniquet is placed on the thigh with the leg elevated. The probe is then placed over a previously marked calf varicosity. On standing the patient and release of the tourniquet, a retrograde flow signal will be present if the sapheno-femoral junction is incompetent.

This note is intended as a guide only. The above **Dopplex**® displays are an indication only. The number of arrows actually displayed will vary according to the **Dopplex**® unit gain setting and probe position. If in doubt contact your local vascular studies unit. If you have any questions regarding the products contact the address below.

References: 1: Bergan J.J. and Yao J.S.T. *Surgery of the Veins*. Grune and Stratton, Orlando, 1984. 2: Browse N.L., Brunard K.G. and Lea Thomas M. *Diseases of the Veins*. Edward Arnold, London, 1988. 3: Folse R. and Alexander R.H. *Directional Flow Detection in Localising Venous Valvular Incompetence*. *Surgery* 1970; 67:114.

Our thanks go to Mr Ian Lane, Medical Director, University Hospital of Wales, Cardiff, UK. and Dr. Mo Aslam, Dept of Surgery, Hammersmith Hospital, London, UK

EDUCATIONAL MATERIAL AVAILABLE FROM HUNTLEIGH DIAGNOSTICS

- Library of Sounds Audio Cassette
- Assessment & Treatment of Leg Ulcers Video
- Vascular Investigations Video
- Assessment of the Diabetic Foot Video
- ABPI & TBPI guides.

Huntleigh Healthcare Inc.
40 Christopher Way, Eatontown, New Jersey 07724-3327
Tel: (800) 223-1218 (732) 578-9898 Fax: (732) 578-9889
www.huntleigh-healthcare.com

APPLICATION NOTES AVAILABLE FROM HUNTLEIGH HEALTHCARE

- NOTE 1** • Arterial Investigation Of The Lower Limb
- NOTE 2** • Venous Investigation Of The Lower Limb Using Doppler
- NOTE 3** • Venous Investigation Of The Lower Limb Using PPG
- NOTE 4** • Screening For The Absence Of An Acute DVT Using PPG
- NOTE 5** • Using A Hand Held Doppler To Assist With PICC Placement

